

# Aggressive Surgery in Palliative Setting of Lung Cancer: Is it Helpful?

Suman Byregowda, Kumar Prabhaskar, Ajay Puri, Amit Joshi, Vanita Noronha, Vijay M Patil, Pankaj Kumar Panda, Ashish Gulia

Departments of Surgical and Medical Oncology, Orthopedic Oncology Services, Tata Memorial Hospital, Mumbai, Maharashtra, India

*Address for correspondence: Dr. Ashish Gulia; E-mail: aashishgulia@gmail.com*

### ABSTRACT

With increase in survival and progression-free survival in the advanced metastatic cancers, the expectation of quality of life (QOL) has increased dramatically. Palliative care plays a vital role in the management of these advanced cancer patients. At present scenario, palliative care in advanced cancer has seen a completely different approach. Aggressive surgical procedures have been performed to improve the QOL in the advanced cancer patients. We report a case of advanced lung cancer with pathological femur fracture, treated with extensive total femur replacement surgery to provide better QOL.

**Key words:** Lung cancer, Multidisciplinary, Palliation, Skeletal metastasis

### INTRODUCTION

Our understanding of the cancer care and disease biology has improved many folds over the last few decades. Majority of lung cancer is treated with palliative intent. In the recent past with better molecular classification and targeted therapy, median survival has improved from 12 months to 60 months in epidermal growth factor receptor (EGFR) mutation-positive patients. As the life expectancy of patients with advanced cancer has increased, their expectation for a better quality of life (QOL) has increased proportionately, especially with incapacitating bony complications. To cater to this high expectation, the boundaries of palliative care have expanded immensely. Approach is shifting from a mere conservative symptomatic relieving strategy to a more aggressive approach which may involve various surgical and minimally invasive procedures to improve the QOL.

Here, we discuss a case of advanced adenocarcinoma of the lung with bony metastasis where a holistic palliative care has not only improved the survival but also improved the QOL.

### CASE REPORT

A 53-year-old male presented with pain and swelling in the left thigh for a duration of 2 weeks, following a trivial trauma. The patient had a significant history of smoking. Local examination revealed hard, tender, circumferential bony swelling arising from diaphysis of the femur. The knee range of movements was normal without any distal neurovascular deficit. Radiograph of the femur revealed an aggressive lytic lesion with wide zone of transition, involving almost entire lower 2/3 of

#### Access this article online

##### Quick Response Code:



Website:  
[www.jpalliativecare.com](http://www.jpalliativecare.com)

DOI:  
10.4103/0973-1075.191859

This is an open access article distributed under the terms of the Creative Commons Attribution-NonCommercial-ShareAlike 3.0 License, which allows others to remix, tweak, and build upon the work non-commercially, as long as the author is credited and the new creations are licensed under the identical terms.

**For reprints contact:** [reprints@medknow.com](mailto:reprints@medknow.com)

**How to cite this article:** Byregowda S, Prabhaskar K, Puri A, Joshi A, Noronha V, Patil VM, Panda PK, Gulia A. Aggressive surgery in palliative setting of lung cancer: Is it helpful?. Indian J Palliat Care 2016;22:504-6.

the femur with associated pathological fracture. Magnetic resonance image done at an outside center showed a lesion arising from diaphysis with a circumferential extraosseous soft tissue component, with disease involving almost the entire length of the femur [Figure 1]. This raised the suspicion of primary neoplasm of the bone. Detailed case history and imaging were discussed in multidisciplinary tumor board meeting, and core needle biopsy was planned with differential diagnosis of primary neoplasm of the bone or a metastatic secondary from a primary elsewhere. The limb was immobilized with Thomas splint to prevent fracture displacement. The patient was bedridden due to pathological fracture, pain, and splint and depended on the family for basic hygiene care.

Histopathological evaluation of core needle biopsy revealed metastatic adenocarcinoma, positive for thyroid transcription factor and cytokeratin 7 and to suspect primary from the lung. Further workup with computed tomography of the thorax revealed a primary in left lung and Tc-99m methylene diphosphonate bone scan showed additional skeletal metastasis in vertebrae. Epidermal growth factor receptor mutation tested on biopsy specimen showed positive for exon 19 in-frame deletion.

In view of gefitinib-sensitive EGFR mutation being positive, the patient was planned to treat with palliative intent with gefitinib and palliative radiation to symptomatic metastatic skeletal lesions. The patient received palliative radiation of 20 Gy to femur lesion and 8 Gy to vertebrae. Bisphosphonates (zoledronic acid) were also added to decrease pain and treat skeletal-related events. On treatment, the patient showed significant improvement in

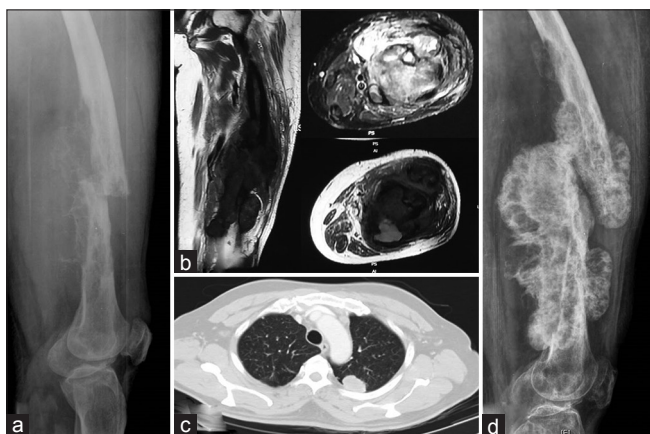general condition, regression in the lung lesion, and healing of the femur pathological fracture.

In view of good response to gefitinib and improvement in general condition, it was decided to treat the femur lesion surgically to improve his QOL. As the disease was involving entire femur, it was excised with oncological principles and the defect was reconstructed with a total femur megaprosthesis [Figure 2]. Postoperative period was uneventful. The patient was made full weight bearing right from the first day after surgery with the help of walker. Along with that knee range of motions were also initiated.

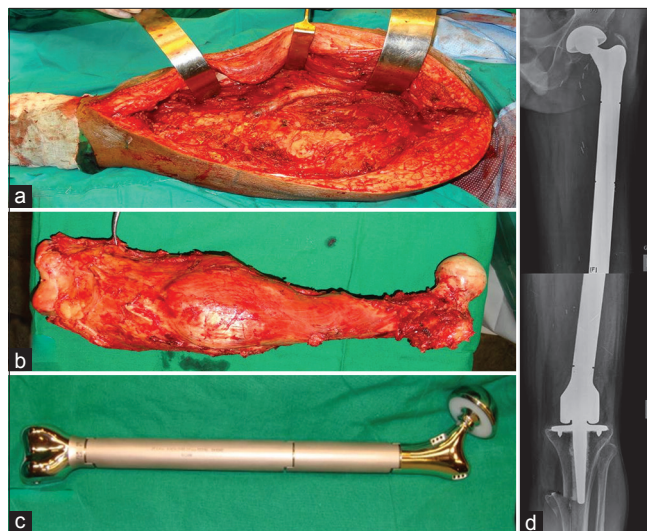
Patient's QOL improved dramatically. He was pain-free and could manage his daily activities independently. His musculoskeletal tumor society score at the last follow-up was 25. Finally, the patient expired with disease progressive after 12 months of surgery.

## DISCUSSION

With increase in survival of advanced carcinoma patients, there is a steep increase in the incidence and prevalence of skeletal-related events secondary to these aggressive tumors, which have preponderance for skeletal system apart from lung and liver.<sup>[1]</sup> Approximately 50% of advanced thyroid and lung carcinoma have skeletal metastasis.<sup>[2]</sup> Most of the skeletal lesions from these cancers cause swift destruction of bone leading which appear as lytic lesions on radiograph and are prone for pathological fractures.



**Figure 1:** (a) Radiograph showing aggressive lytic lesion in diaphysis of the femur with pathological fracture (b) magnetic resonance image showing lesion involving entire length of the femur with soft-tissue component (c) computed tomographic image showing primary lung carcinoma (d) radiograph showing healed pathological fracture with good calcification of lesion, indicating good treatment response



**Figure 2:** (a) Intraoperative picture showing defect following the total femur excision (b) total femur excised with good oncological margins (c) modular total femur prosthesis equal to the length of the patient's femur was reconstructed (d) radiograph showing total femur prosthesis at 9 months of follow-up

The probability of pathological fracture from the skeletal metastasis varies from 10 to 29% which is higher with lung, thyroid, and kidney lesions as compared to metastasis from breast and prostate as these are osteoblastic in nature.<sup>[3]</sup> These skeletal events are the cause of major morbidity and deterioration of QOL. Various surgical and nonsurgical ways are employed to decrease this morbidity and promote an independent-improved QOL.

Our patient was diagnosed to have adenocarcinoma of the lung with skeletal metastasis, so the patient was decided to treat with palliative intent. Epidermal growth factor receptor tyrosine kinase inhibitions have paved the way for targeted therapies in lung cancer. As the patient was positive for EGFR mutation, call was taken to treat the patient with gefitinib to improve the disease progressive-free survival and overall survival. Randomized clinical trial by Sellmann *et al.* has shown significant improvement in overall survival (46.9 vs. 21.0 months,  $P = 0.036$ ) between gefitinib-treated EGFR mutation-positive patients and EGFR mutation-positive patients treated with placebo in advanced nonsmall cell carcinoma.<sup>[4]</sup> Tyrosine kinase inhibitors have also been proven safe in elderly patient with minimal toxicity.<sup>[5]</sup>

Femur skeletal metastasis was initially treated with palliative radiation for pain control as the surgery such as total femur replacement was thought to be morbid considering patient age, general condition, and extensive disease.<sup>[6]</sup> As the general condition dramatically improved on treatment and regression of primary and metastatic lesions, decision was taken to treat the pathological fracture femur to improve the QOL. The main aims while considering an orthopedic reconstruction in a metastatic disease are (a) the procedure should be durable, should lose more than the expected survival of the patient, (b) should allow immediate mobilization of the patient, and (c) should be cost-effective.<sup>[7]</sup> In view of extensive involvement of the femur with pathological fracture and considering the above-mentioned aims for the reconstruction in secondary, a cemented total femur replacement was planned. The advantages with endoprosthesis are immediate mobilization, less hospital stay, durable, and stable construct and fewer complications. Hattori *et al.* performed megaprosthesis reconstruction for femur lesions on 22 patients with an anticipated survival of more than 6 months and concluded that megaprosthesis replacement significantly improves QOL with satisfactory functional outcome and lower complications.<sup>[8]</sup> The other biggest advantage is the easily

available, indigenously manufactured low-cost modular total femoral prosthesis which is affordable to low socioeconomic groups of developing countries. Puri *et al.* have shown excellent function and 5-year implant survival up to 88% with this low-cost prosthesis in primary bone tumors.<sup>[9]</sup>

## CONCLUSION

Palliative treatment does not end with medical management. In the present era with significant improvement in the progression-free survival and overall survival of advanced carcinomas, aggressive multidisciplinary approach can dramatically improve the QOL and functional outcome in these patients. Proper selection of the patients and multidisciplinary teamwork hold the key for the better outcomes.

## Financial support and sponsorship

Nil.

## Conflicts of interest

There are no conflicts of interest.

## REFERENCES

1. Rubens RD, Mundy GR. Cancer and the Skeleton. London (UK): Martin Dunitz; 2000.
2. Rosen LS, Gordon D, Kaminski M, Howell A, Belch A, Mackey J, *et al.* Long-term efficacy and safety of zoledronic acid compared with pamidronate disodium in the treatment of skeletal complications in patients with advanced multiple myeloma or breast carcinoma: A randomized, double-blind, multicenter, comparative trial. *Cancer* 2003;98:1735-44.
3. Aaron AD. Treatment of metastatic adenocarcinoma of the pelvis and the extremities. *J Bone Joint Surg Am* 1997;79:917-32.
4. Sellmann L, Fenchel K, Dempke WC. Improved overall survival following tyrosine kinase inhibitor treatment in advanced or metastatic non-small-cell lung cancer-the holy grail in cancer treatment? *Transl Lung Cancer Res* 2015;4:223-7.
5. Minuti G, D'Incecco A, Cappuzzo F. Current and emerging options in the management of EGFR mutation-positive non-small-cell lung cancer: Considerations in the elderly. *Drugs Aging* 2015;32:907-16.
6. Lutz S, Berk L, Chang E, Chow E, Hahn C, Hoskin P, *et al.* Palliative radiotherapy for bone metastases: An ASTRO evidence-based guideline. *Int J Radiat Oncol Biol Phys* 2011;79:965-76.
7. Chan D, Carter SR, Grimer RJ, Sneath RS. Endoprosthetic replacement for bony metastases. *Ann R Coll Surg Engl* 1992;74:13-8.
8. Hattori H, Mibe J, Yamamoto K. Modular megaprosthesis in metastatic bone disease of the femur. *Orthopedics* 2011;34:e871-6.
9. Puri A, Gulia A, Chan WH. Functional and oncologic outcomes after excision of the total femur in primary bone tumors: Results with a low cost total femur prosthesis. *Indian J Orthop* 2012;46:470-4.