

Letter to Editor

Trocar Catheter: A New Alternative for Point of Care for Management of Pleural Effusion by Palliative Care Physicians

Himanshu Varshney¹ , Prateek Maurya¹ , Sachidanand Jee Bharati¹ , Nishkarsh Gupta¹

¹Department of Onco-Anaesthesia and Palliative Medicine, DRBRAIRCH, All India Institute of Medical Sciences, New Delhi, India.

Dear Editor,

We would like to highlight the use of trocar catheters as a minimally invasive alternative for managing malignant pleural effusion (MPE) in palliative care, based on our experience with a critically ill cancer patient. MPE affects up to 20% of cancer patients, contributing to significant morbidity, including severe dyspnoea, pain and reduced mobility.^[1] Traditional management with large-bore intercostal chest drains (ICDs) requires surgical incisions and muscle dissection, often resulting in complications such as hemothorax, pneumothorax, organ perforation and infections.^[2] These risks can be especially burdensome for palliative care patients. While the use of pigtail catheters has been explored, there is limited research on the efficacy of trocar catheters compared to ICDs.^[3] Studies, such as by Abusedera and Alkady, demonstrate that trocar catheters achieve high technical success rates (96%) with low complication rates, making them a viable alternative for MPE management in palliative care.^[4]

We recently managed a 70-year-old female with advanced ovarian carcinoma and peritoneal metastases presenting with massive MPE, characterised by severe dyspnoea (Modified Medical Research Council scale grade 4) and intense chest pain (8/10 on the Numeric Rating Scale) [Figure 1]. Her pre-procedure Eastern Cooperative Oncology Group Performance Status (ECOG PS) was 3, reflecting significant functional impairment and limited tolerance for invasive procedures. Considering her frailty, recurrent MPE and preference for early discharge, a trocar catheter was chosen over an ICD.

The procedure was performed using the Seldinger technique, with a 24-gauge trocar catheter inserted under

sterile conditions [Figure 2]. Immediate drainage of 2 L of haemorrhagic fluid provided significant symptomatic relief, with her dyspnoea and chest pain reducing to 2/10. Her performance status improved from ECOG PS 3–2, allowing for greater independence. The total procedure time was 14 min, shorter than the approximately 15–30 min required for ICD placement, due to the streamlined nature of trocar catheter insertion, which avoids extensive muscle dissection [Table 1].^[5]

The patient was monitored for 6 h post-procedure, remained stable and was discharged with instructions for catheter care and outpatient follow-up. On day 7, follow-up revealed full lung expansion, and the catheter was successfully removed [Figure 1]. The minimally invasive approach facilitated early discharge and reduced the overall burden of care, aligning with palliative care objectives.

Trocar catheters offer several advantages over traditional ICDs. They minimise procedural pain and scarring, providing rapid symptomatic relief and significant improvement in respiratory function and mobility as well as a reduction in psychosocial distress, including relief from anxiety and fear of suffocation. Compared to pigtail catheters, which may clog in haemorrhagic effusions, trocar catheters offer reliable drainage and are less invasive than ICDs, making them a compassionate choice for MPE management.^[6]

The ease of use in non-surgical settings, coupled with reduced post-procedural care requirements, makes them practical for palliative care physicians. Post-procedural care was minimal, involving routine flushing with heparinised saline, incentive spirometry and chest physiotherapy. Furthermore, trocar catheters are cost-effective, priced at 500–600 Indian rupees

*Corresponding author: Nishkarsh Gupta, Department of Onco-Anaesthesia and Palliative Medicine, DRBRAIRCH, All India Institute of Medical Sciences, New Delhi, India. drnishkarsh@rediffmail.com

Received: 23 October 2024 Accepted: 17 December 2024 Epub Ahead of Print: 24 January 2025 Published: XXXXXXXX DOI: 10.25259/IJPC_303_2024

This is an open-access article distributed under the terms of the Creative Commons Attribution-Non Commercial-Share Alike 4.0 License, which allows others to remix, transform, and build upon the work non-commercially, as long as the author is credited and the new creations are licensed under the identical terms.

©2025 Published by Scientific Scholar on behalf of Indian Journal of Palliative Care

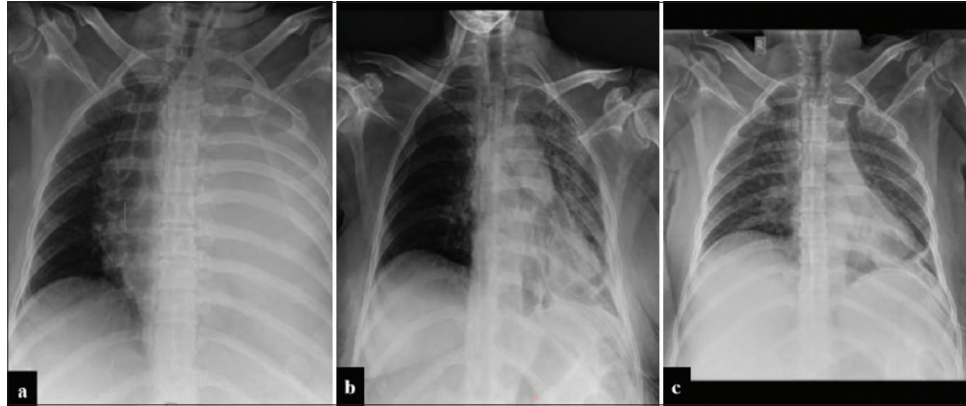


Figure 1: (a) is the baseline chest X-ray showing a complete whiteout lung with mediastinal deviation to the right side, (b) is a post-procedural chest X-ray showing the expansion of the left lung with trocar catheter *in situ* at the base of the left lung and (c) is chest X-ray after 7 days showing full expansion of left lung with trocar catheter *in situ*.

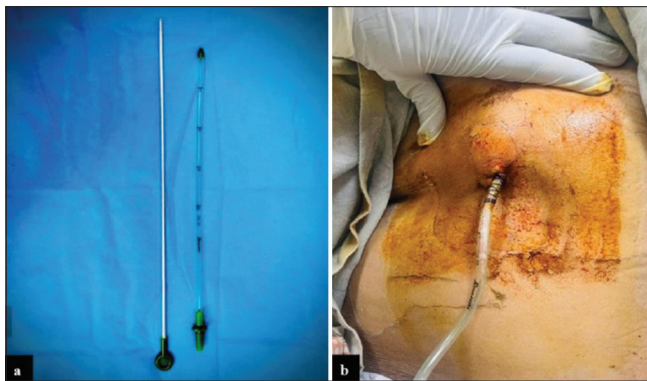

Figure 2: (a) Shows the Trocar catheter with pointed tip encircled and (b) shows the patient having a 24 G trocar catheter *in situ*.

Table 1: Comparison of time taken for steps in trocar catheter insertion and ICD insertion procedures.

| Steps of procedure | Time taken in trocar catheter insertion | Time taken in ICD insertion |
|-----------------------|---|-----------------------------|
| Painting and draping | 5 min | 5 min |
| Local Anaesthesia | 2 min | 2 min |
| Catheter Insertion | 1–2 min | 7–10 min |
| Suturing and dressing | 5 min | 5 min |
| Total | 13–14 min | 19–22 min |

ICD: Intercostal chest drain

(INR), significantly lower than pigtail catheters (~1500 INR) and comparable to ICDs (300–500 INR), making them a viable option in resource-constrained settings.

Despite these advantages, trocar catheters carry risks such as re-expansion pulmonary oedema, infections and catheter dislodgement. Challenges include loculated pleural effusions, coagulopathies and hemodynamic instability. Further comparative studies are needed to substantiate their efficacy

and establish trocar catheters as a standard option for MPE management.

This case demonstrates that trocar catheters are a patient-centred, minimally invasive and cost-effective alternative for MPE management, particularly in palliative care settings. They align well with the goals of reducing procedural distress, enabling rapid recovery and improving quality of life. We advocate for further research into trocar catheters to validate their broader adoption and long-term outcomes in similar settings.

Ethical approval

The Institutional Review Board approval is not required.

Declaration of patient consent

The authors certify that they have obtained all appropriate patient consent.

Financial support and sponsorship

Nil.

Conflicts of interest

There are no conflicts of interest.

Use of artificial intelligence (AI)-assisted technology for manuscript preparation

The authors confirm that there was no use of artificial intelligence (AI)-assisted technology for assisting in the writing or editing of the manuscript and no images were manipulated using AI.

REFERENCES

1. Scherpereel A, Astoul P, Baas P, Berghmans T, Clayson H, de Vuyst P, et al. Guidelines of the European Respiratory Society and the European Society of Thoracic Surgeons for the Management of Malignant Pleural Mesothelioma. *Eur Respir J* 2010;35:479-95.
2. Miller KS, Sahn SA. Chest Tubes: Indications, Technique, Management and Complications. *Chest* 1987;91:258-64.

3. Liu CM, Hang LW, Chen WK, Hsia TC, Hsu WH. Pigtail Tube Drainage in the Treatment of Spontaneous Pneumothorax. *Am J Emerg Med* 2003;21:241-4.
4. Abusedera M, Alkady O. Ultrasound-guided Pleural Effusion Drainage with a Small Catheter Using the Single-step Trocar or Modified Seldinger Technique. *J Bronchol Intervent Pulmonol* 2016;23:138-45.
5. Ashita ET, Anupama KP, Anilkumar VR, Sreekar AP. Assessment of Surgical Outcome of Trocar versus Blunt Dissection Technique for Intercostal Drainage Insertion: A Prospective Interventional Study. *Int J Anat Radiol Surg* 2024;13:SO13-7.
6. Tsai WK, Chen W, Lee JC, Cheng WE, Chen CH, Hsu WH, *et al.* Pigtail Catheters vs Large-bore Chest Tubes for Management of Secondary Spontaneous Pneumothoraces in Adults. *Am J Emerg Med* 2006;24:795-800.

How to cite this article: Varshney H, Maurya P, Bharati SJ, Gupta N. Trocar Catheter: A New Alternative for Point of Care for Management of Pleural Effusion by Palliative Care Physicians. *Indian J Palliat Care*. doi: 10.25259/IJPC_303_2024