



Case Report

Management of Malignant Ascites by Indwelling Tunnelled Catheters in Indian Setup: A Case Series

Praneeth Suvvari¹, Abhijit Nair², Srinivasa Shyam Prasad Mantha¹, Mohammad Salman Saifuddin¹, Vibhavari Naik¹, Basanth Kumar Rayani¹

¹Department of Oncoanaesthesia, Pain and Palliative Medicine, Basavatarakam Indo-American Cancer Hospital and Research Institute, Hyderabad, Telangana, India, ²Department of Anaesthesiology, Ibra Hospital, Ibra, Muḥāfazat Janūb ash Sharqiyah, Oman.



*Corresponding author:

Praneeth Suvvari,
Department of
Oncoanaesthesia, Pain
and Palliative Medicine,
Basavatarakam Indo-American
Cancer Hospital and Research
Institute, Hyderabad,
Telangana, India.

praneethsuv@gmail.com

Received : 18 November 2020

Accepted : 31 May 2021

Published : 12 August 2021

DOI

10.25259/IJPC_416_20

ABSTRACT

Malignant Ascites (MA) poses significant symptom burden in patients with peritoneal malignancies at the end of life. Various treatment options are available and Indwelling Tunnelled Catheters (ITC) have the advantage of increased patient comfort being soft on abdomen, less painful, easy to tap fluid, and less chances of infection etc. A total of 5 patients underwent insertion of ITC after proper counseling and assessment. Insertion was done in operation theatre under combined ultrasonogram and fluoroscopy guidance. Results: 4 out of 5 patients had favorable outcomes in terms of symptom free days spent at home at end of life. ITC's are a suitable option to manage symptoms in patients with terminal malignant ascites. Careful patient selection and proper education of the caregivers will increase the success rates of procedures.

Keywords: Ascites, Indwelling catheters, Malignancy, Palliative care

INTRODUCTION

Ascites is a common manifestation seen in several benign and malignant diseases, often causing more distress than the underlying pathology itself.^[1] Malignant ascites (MA) is an abnormal accumulation of fluid in the peritoneal cavity because of cancer and approximately accounts for 10% of all cases of ascites.^[2]

MA poses significant symptom burden at end of life in patients with advanced neoplasms. Effective palliation of symptoms including respiratory and gastrointestinal associated with abdominal discomfort is often difficult to achieve.^[3] Increased intra-abdominal pressure induced by MA may cause abdominal pain, nausea, anorexia, respiratory distress, reduced mobility and cosmetic and psychological problems, including depression, all of which adversely affect quality of life.^[4]

Various treatment options such as repeated paracentesis, diuretics, tunnelled and non-tunnelled indwelling catheters, intraperitoneal chemotherapy and peritoneovenous shunts have been tried previously.^[5] Each treatment option has its own merits and demerits.

Repeated paracentesis has the disadvantages such as repeated hospital visits, increased travel costs and admission costs. Furthermore, repeated large volume paracentesis is associated with multiple complications such as pain due to multiple needle puncture, hypotension, infection, intestinal perforation, hypoproteinaemia, secondary peritonitis, fatigue, dizziness and nausea

This is an open-access article distributed under the terms of the Creative Commons Attribution-Non Commercial-Share Alike 4.0 License, which allows others to remix, tweak, and build upon the work non-commercially, as long as the author is credited and the new creations are licensed under the identical terms.

©2021 Published by Scientific Scholar on behalf of Indian Journal of Palliative Care

contributes to the patient's dissatisfaction.^[6] Patients often delay their hospital visit due to discomfort caused by procedure and wait till they experience a high level of pain and abdominal distension before scheduling their next visit. Frequent hospital visits not only affect the quality of life of the patient but also increase the caregiver burden.^[7,8]

Tunnelled indwelling catheters are designed to remain *in situ* indefinitely for the remaining lifespan of the patient. The polyester cuff in the tunnelled portion of the catheter promotes tissue fibrosis, reduces chances of infection and avoids inadvertent catheter dislodgement. Tunnelling of the catheter is believed to reduce infection risks, though this has not been formally tested. The one-way valve at the distal end of the catheter permits drainage of ascitic fluid: The catheter can be 'opened' and connected to drainage devices when needed, while at other times, the patient can continue usual daily activities with the catheter capped off.^[9] This permits home drainage of ascitic fluid and improved comfort level for the patient. Disadvantages with these catheters are high costs and limited availability in our country.

The purpose of this case series is to put forward our experiences in managing patients with terminal MA using indwelling tunnelled catheters (ITCs) (Rocket IPC Mini, USA).

CASE REPORT

Any patient requiring frequent tapping was counselled about the procedure. As the catheter is costly, patients are already drained off money for treatment and it is not covered in the government scheme in our state, we usually get few patients who eventually agree for the procedure. Most of the patients have been tried with chemotherapy or radiation before referral for our pain clinic for catheter insertion. Five patients with MA requiring repeated paracentesis were selected for ITC insertion [Table 1]. Patients and caregivers were initially counselled on the advantages of ITC and the costs of insertion. They were shown videos on how to drain the fluid at home by maintaining aseptic precautions while draining fluid. Written informed consent was obtained from the patients and attenders before procedure. Screening ultrasound was done a day before mark for the site of puncture and to ensure that there are no loculations of ascitic fluid in abdominal cavity. Patients were asked to have light breakfast on the morning of procedure.

Insertion method

Inside the operation theatre, abdomen was cleaned with 0.5% w/v chlorhexidine and adequate drapes were applied.

Table 1: Details of the patients who were managed with indwelling tunneled catheters.

S. No.	Diagnosis	Previous treatment	No. of living days with catheter <i>in situ</i>	Complications/side effects/comments
1	Ca stomach	Distal subtotal radical gastrectomy followed by FLOT chemotherapy	1	1. Patient had recurrence of pleural effusion and ARDS next day after insertion of peritoneal catheter. Caregivers opted for supportive care and refused pleural tap 2. Patient expired in medical ICU
2	Ca lung relapse	Right upper lobectomy followed by 6 cycles pemetrexed + carboplatin f/b pemetrexed + gemcitabine	43	1. Slight discomfort on sleeping on same side of catheter 2. Comfortably died at home
3	Ca pancreas with liver metastasis	Received radical RT 30 fractions to abdomen by TomoTherapy	57	1. Patient had pericatheter leak of ascites fluid at catheter entry site on day 7. Managed with applying a suture around catheter 2. Comfortably died at home
4	Ca stomach	4 cycles of Capecitabine + Oxaliplatin	23	1. Pericatheter leak on day 10 of insertion. Managed with dressing alone as leak was mild 2. Comfortably died at home
5	Hepatocellular carcinoma in a patient with cirrhotic liver disease	Started on tab. sorafenib (TACE/SBRT was not indicated in view of large size of tumour)	28	1. Dilator and tear away sheath assembly got damaged insertion. Surgical assistance was sought during procedure 2. Penile and testicular swelling was noted on the 2 nd post-operative day. It was coincidental finding and unrelated to catheter insertion 3. Patient developed pleural effusion after 28 days and expired at home due to increasing respiratory distress

FLOT: Docetaxel, oxaliplatin, leucovorin and 5-fluorouracil, ARDS: Acute respiratory distress syndrome, Ca: Carcinoma, f/b: Followed by. RT: Radiotherapy, ICU: Intensive care unit, TACE: Trans-arterial chemoembolisation, SBRT: Stereotactic body radiation therapy

The left lower quadrant of the abdomen was usually selected for the entry point of the catheter as caecum is relatively fixed on the right side. Catheter was inserted under combined ultrasound and fluoroscopic technique. Under sonographic guidance, intraperitoneal space was accessed with an 18G Chiba needle. A sample of about 10 mL of ascites fluid was collected for laboratory analysis. Under fluoroscopic guidance, stiff guidewire was advanced to the most dependent part of the pelvis and its position confirmed with fluoroscopy [Figure 1]. Small incision was given at needle insertion site and after serial dilatation of the tract, a dilator, tear away sheath assembly was placed in the peritoneal cavity over the stiff guidewire. A second incision was made approximately 5 cm superolateral to the first incision.

The local anaesthetic was injected into the tunnel tract. The metal tunnelling device was advanced through the tract with the peritoneal catheter attached to its backside. It was ensured while tunnelling that the cuff was placed in the middle of the tunnelled tract. Dilator and guide wire are then removed keeping the tear away sheath intact. A finger can be kept to occlude backflow of the peritoneal fluid. The catheter was placed in the most dependent part of the pelvic cavity through the peel-away sheath, and then, the peel-away sheath was removed. The skin was closed with primary suturing and protective dressing was applied [Figure 2].

After the completion of procedure, the patient was shifted to recovery area, and in the presence of patient attender, drainage procedure was explained again and demonstrated [Figure 3]. Three–4 litres of ascitic fluid were drained and patients were discharged after 1 h of observation. Frequency of drainage at home was guided based on patient symptom burden. Patients were provided pain clinic telephone number and were advised to contact for any queries.

DISCUSSION

Peritoneal dialysis catheter was first reported for palliation of MA by interventional radiologists in 2001.^[10] Several

catheters including PleurX catheter (Rocket IPC), Tenckhoff catheter and peritoneal dialysis catheter including tunnelled haemodialysis catheter have been used for the same purpose.^[4] There has been no consensus established yet regarding the efficacy of a single best catheter.^[11] Each has their own merits and demerits.

We selected five patients for catheter insertion [Table 1]. Except in one patient, we had favourable outcomes in other four patients. The patient in whom we did not have good outcome had a coexisting pleural effusion which was not symptomatic till the day of procedure. He had relief in abdominal distension, pain and breathlessness immediately after procedure, but it was short lived. He was shifted to ICU day after the procedure with exacerbation of breathlessness and not able to maintain saturation with oxygen and facemask. On imaging, he had pleural effusion with acute respiratory distress syndrome. The family opted for supportive care and the patient died in intensive care unit subsequently.

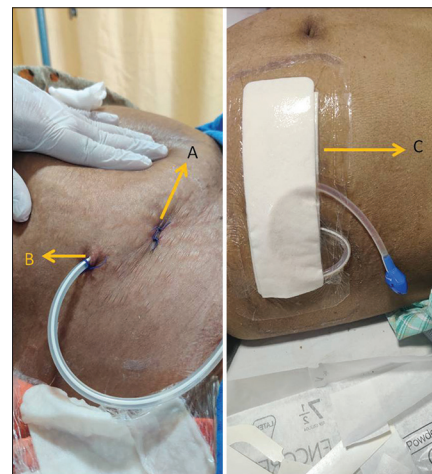

Figure 2: Tunnelled catheter in place with entry and exit sites and after applying protective dressing. A: Catheter entry point, B: Catheter exit point, C: Protective dressing.

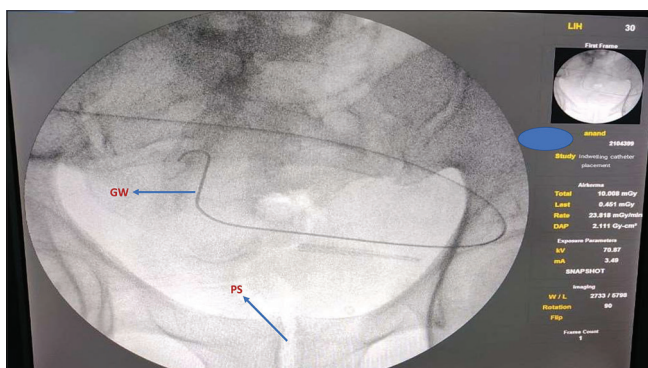


Figure 1: Guidewire placed in the most dependant part of pelvis as visualised by fluoroscopy. PS: Pubic symphysis, GW: Guidewire.

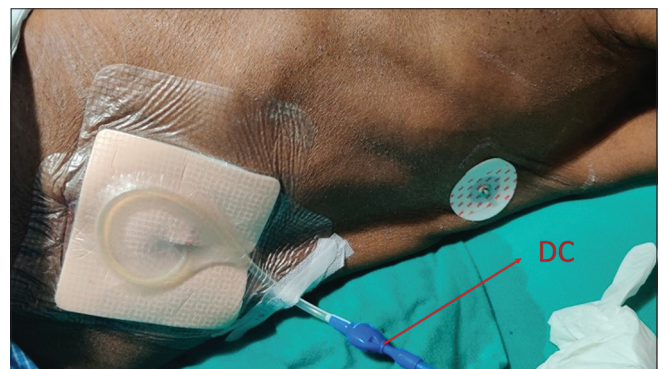

Figure 3: Drainage catheter is attached to tunnelled catheter and ascitic fluid being drained. DC: Drainage catheter.

In one patient, dilator and tear away sheath assembly got damaged during railroading over the guidewire in operation theatre. Surgical assistance was sought during procedure for catheter insertion. Vascular forceps was used to dilate over the guidewire to accommodate the catheter and catheter was later threaded over the guidewire manually. In the same patient, penile and testicular swelling were noted on the 2nd post-operative day. There was no problem during micturition and no pain in the affected area. No redness or signs of inflammation were noted during clinical examination of testis. Ultrasound testis revealed extensive scrotal wall oedema and minimal hydrocoele. The patient was advised scrotal support and advised to elevate testis and penis with a folded towel underneath to reduce the swelling. We initially suspected one eye of drainage catheter to be misplaced within the subcutaneous tissue and causing the oedema. To rule out whether one draining eye of catheter is misplaced in subcutaneous tissue, we have injected Gastrografin dye[®] (diatrizoate meglumine and diatrizoate sodium solution) and checked the catheter position with fluoroscopy imaging. Dye spread was noted only in peritoneal cavity. The patient was counselled about scrotal elevation and sent to home. On follow-up, the swelling reduced on the 5th post-operative day and was found to be unrelated to catheter insertion.

None of the patients had catheter site infections. They were advised to change protective dressing every 3–5 days with adequate aseptic precautions that can be followed at home. Two patients had slight pericatheter leak that was managed with securing a suture around the leak site and applying Truseal (N-Butyl-2-Cyanoacrylate gel) later at the same site. One patient complained of pain on sleeping on the same side of catheter. Catheter site was inspected but there were no signs of infection. The patient was counselled to sleep on opposite side. All the patients had concomitant pain which was managed according to the WHO analgesic ladder.^[12]

Narayanan *et al.*, in 2014, published a retrospective study in 38 patients in whom PleurX catheter was used to manage MA. Complications in their patients were, three had pain, two had infections, two reported leakage, two catheters had to be removed due to insufficient drainage, one accidental catheter removal and one patient had sleep disturbance.^[13] In a prospective analysis by Tapping *et al.*; out of 28 patients, five had discomfort with erythema and discharge, there were four accidental dislodgements, one had leakage and one patient reported incision site hernia.^[14] Meier *et al.* in a retrospective case series of 20 patients reported six transient soreness, two leakage and one dislocation.^[15] Although we have reported similar complications compared to the previous studies, we could not compare the incidences of complications in

our study population with other authors as our analysis has been done only in five patients.

CONCLUSION

ITCs are a suitable option to manage symptoms in patients with terminal MA. Careful patient selection and proper education of the caregivers will increase the success rate of procedures. Drawbacks of ITCs are its high costs, limited availability and expertise needed to perform the procedure. Patients should be counselled regarding possibility of pericatheter leaks which is although distressing and can be managed by conservative measures.

Declaration of patient consent

Patient's consent not required as there are no patients in this study.

Financial support and sponsorship

Nil.

Conflicts of interest

There are no conflicts of interest.

REFERENCES

- Orsi F, Grasso RF, Bonomo G, Monti C, Marinucci I, Bellomi M. Percutaneous peritoneovenous shunt positioning: Technique and preliminary results. *Eur Radiol* 2002;12: 1188-92.
- Becker G, Galandi D, Blum HE. Malignant ascites: Systematic review and guideline for treatment. *Eur J Cancer* 2006;42: 589-97.
- Sabatelli FW, Glassman ML, Kerns SR, Hawkins IF Jr. Permanent indwelling peritoneal access device for the management of malignant ascites. *Cardiovasc Intervent Radiol* 1994;17:292-4.
- Kaya A, Nas OF, Erdogan C. Tunneled peritoneal catheter placement in palliation of malignant ascites: A study with two different types of catheters. *Biomed Res Int* 2019;2019:4132396.
- Ammouri L, Prommer EE. Palliative treatment of malignant ascites: Profile of catumaxomab. *Biologics* 2010;4:103-10.
- Sangisetty SL, Miner TJ. Malignant ascites: A review of prognostic factors, pathophysiology and therapeutic measures. *World J Gastrointest Surg* 2012;4:87-95.
- Suvvari P, Nair A, Anne P, Rayani BK. Innovative method to deal with pericatheter leak in home-based management of malignant ascites. *Indian J Palliat Care* 2020;26:394.
- Ratre BK, Suvvari P, Hoda W, Roychoudhury P, Bharti SJ, Bhatnagar S. Central Venous catheter as peritoneal indwelling catheter for the management of recurrent malignant ascites: A case series. *Indian J Palliat Care* 2019;25:57-60.
- Boshuizen RC, Thomas R, Lee YC. Advantages of indwelling pleural catheters for management of malignant pleural

- effusions. *Curr Respir Care Rep* 2013;2:93-9.
10. O'Neill MJ, Weissleder R, Gervais DA, Hahn PF, Mueller PR. Tunneled peritoneal catheter placement under sonographic and fluoroscopic guidance in the palliative treatment of malignant ascites. *AJR Am J Roentgenol* 2001;177:615-8.
 11. Maleux G, Indesteege I, Laenen A, Verslype C, Vergote I, Prenen H. Tenckhoff tunneled peritoneal catheter placement in the palliative treatment of malignant ascites: Technical results and overall clinical outcome. *Radiol Oncol* 2016;50:197-203.
 12. Anekar AA, Cascella M. WHO Analgesic Ladder. Treasure Island, FL: StatPearls Publishing; 2020.
 13. Narayanan G, Pezeshkmehr A, Venkat S, Guerrero G, Barbery K. Safety and efficacy of the PleurX catheter for the treatment of malignant ascites. *J Palliat Med* 2014;17:906-12.
 14. Tapping CR, Ling L, Razack A. PleurX drain use in the management of malignant ascites: Safety, complications, long-term patency and factors predictive of success. *Br J Radiol* 2012;85:623-8.
 15. Meier M, Mortensen FV, Madsen HH. Malignant ascites in patients with terminal cancer is effectively treated with permanent peritoneal catheter. *Acta Radiol Open* 2015;4:2058460115579934.

How to cite this article: Suvvari P, Nair A, Mantha SS, Saifuddin MS, Naik V, Rayani BK. Management of malignant ascites by indwelling tunnelled catheters in Indian setup: A case series. *Indian J Palliat Care* 2021;27(2):349-53.